

Repair of a large patellar cartilage defect using human umbilical cord blood-derived mesenchymal stem cells: A case report

Jun-Seob Song, Ki-Taek Hong, Ki Jeon Song, Seok Jung Kim

Specialty type: Orthopedics

Provenance and peer review:

Unsolicited article; Externally peer reviewed.

Peer-review model: Single blind

Peer-review report's scientific quality classification

Grade A (Excellent): 0

Grade B (Very good): 0

Grade C (Good): C, C

Grade D (Fair): 0

Grade E (Poor): 0

P-Reviewer: Chen C, China; Yang B, China

Received: July 10, 2022

Peer-review started: July 10, 2022

First decision: August 22, 2022

Revised: September 10, 2022

Accepted: November 2, 2022

Article in press: November 2, 2022

Published online: December 6, 2022



Jun-Seob Song, Ki-Taek Hong, Department of Orthopedic Surgery, Gangnam JS Hospital, Seoul 06053, South Korea

Ki Jeon Song, Seok Jung Kim, Department of Orthopedic Surgery, Uijeongbu Street Mary's Hospital, College of Medicine, The Catholic University of Korea, Uijeongbu 11765, Gyeonggi-do, South Korea

Corresponding author: Seok Jung Kim, FRCS, MD, PhD, Director, Full Professor, Department of Orthopedic Surgery, Uijeongbu Street Mary's Hospital, College of Medicine, The Catholic University of Korea, No. 271 Cheonbo-ro, Uijeongbu 11765, Gyeonggi-do, South Korea.
peter@catholic.ac.kr

Abstract

BACKGROUND

Patellar dislocation may cause cartilage defects of various sizes. Large defects commonly require surgical treatment; however, conventional treatments are problematic.

CASE SUMMARY

A 15-year-old male with a large patellar cartilage defect due to patellar dislocation was treated *via* human umbilical cord blood-derived mesenchymal stem cell (hUCB-MSC) implantation. To our knowledge, this is the first report of this treatment for this purpose. The patient recovered well as indicated by good visual analog scale, International Knee Documentation Committee and McMaster Universities Osteoarthritis Index scores. Magnetic resonance imaging showed cartilage regeneration 18 mo postoperatively.

CONCLUSION

Umbilical cord blood-derived hUCB-MSCs may be a useful treatment option for the repair of large patellar cartilage defects.

Key Words: Cartilage defect; Umbilical cord; Mesenchymal stem cells; Patellar dislocation; Magnetic resonance imaging; Case report

©The Author(s) 2022. Published by Baishideng Publishing Group Inc. All rights reserved.

Core Tip: Umbilical cord blood-derived mesenchymal stem cells consist of a unique population of progenitors co-expressing mesenchymal stem cells and neuronal markers capable of instantaneous differentiation. This report is of a 15-year-old male teen with a large patellar cartilage defect due to patellar dislocation who was treated with implantation of human umbilical cord blood-derived mesenchymal stem cells.

Citation: Song JS, Hong KT, Song KJ, Kim SJ. Repair of a large patellar cartilage defect using human umbilical cord blood-derived mesenchymal stem cells: A case report. *World J Clin Cases* 2022; 10(34): 12665-12670

URL: <https://www.wjgnet.com/2307-8960/full/v10/i34/12665.htm>

DOI: <https://dx.doi.org/10.12998/wjcc.v10.i34.12665>

INTRODUCTION

Patellar cartilage defects often accompany acute patellar dislocation[1]. Small cartilage defects can be treated conservatively or *via* microfracture. Large cartilage defects may cause problems, such as anterior knee pain and arthritis, and require cartilage repair treatment.

Treatment of large patellar cartilage defects *via* autologous chondrocyte implantation (ACI) or osteochondral autologous transplantation (OAT) has been reported[1,2]. ACI, a two-step procedure, is time-consuming and expensive, and OAT can cause problems at the harvest site of the osteochondral plug. To avoid these shortcomings, alternative treatment methods, especially those using mesenchymal stem cells (MSCs) have been evaluated recently[3].

We use human umbilical cord blood-derived MSCs (hUCB-MSCs) for cartilage repair. Compared with other MSCs, hUCB-MSCs have better cell activity and do not require invasive procedures for collection. Regardless of the cartilage defect size, the desired amount of the hUCB-MSCs can be prepared at any time[4,5]. To the best of our knowledge, there have been no reports of large patellar cartilage defects treated with hUCB-MSCs. This report presents such a case.

CASE PRESENTATION

Chief complaints

Left knee pain and swelling.

History of present illness

A 15-year-old male had fallen while running the day before.

History of past illness

There is no history of past illness.

Personal and family history

There is no personal and family history.

Physical examination

Swelling and limitation of knee motion.

Laboratory examinations

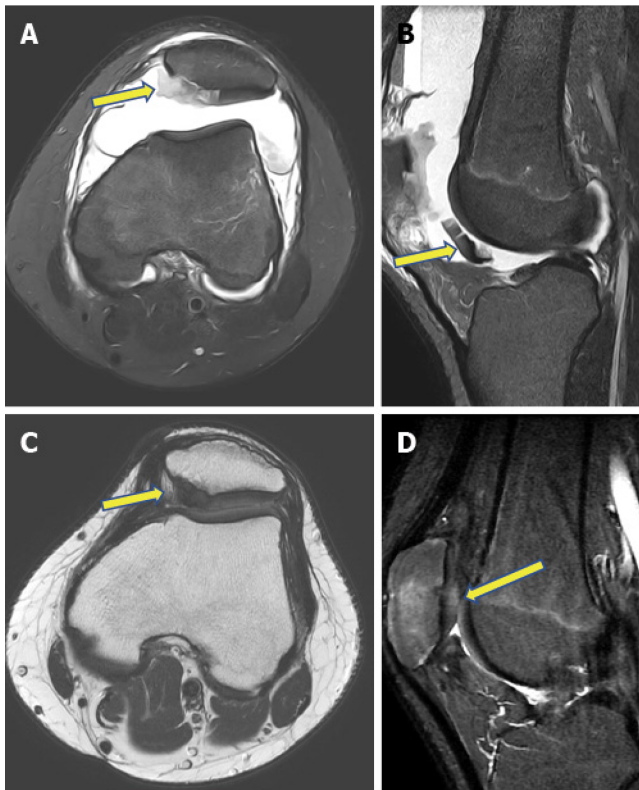
No specific findings.

Imaging examinations

Radiography showed patellar dislocation. Magnetic resonance imaging (MRI) revealed a large amount of hemarthrosis, a medial patellofemoral ligament tear and a 4.92 cm² (2.04 cm × 2.41 cm) patellar cartilage defect (Figure 1A and B).

FINAL DIAGNOSIS

Patellar dislocation with large patellar cartilage defects.



DOI: 10.12998/wjcc.v10.i34.12665 Copyright ©The Author(s) 2022.

Figure 1 Magnetic resonance images. A: T2-weighted, a fat-suppressed axial image showing a cartilage defect (arrow) on the medial side of the patella and patellar dislocation with a medial patellofemoral ligament tear; B: T2-weighted, a fat-suppressed sagittal image showing a large amount of hemarthrosis and detached patellar cartilage (arrow) in the infrapatellar area; C: Proton density axial image showing regeneration of the patellar cartilage (arrow) and a normal patellar position, with the healing of the medial patellofemoral ligament, 18 mo after surgery; D: Proton fat-suppressed sagittal image showing patellar cartilage regeneration (arrow) 18 mo after surgery.

TREATMENT

After routine arthroscopy for loose body removal and joint debridement, a skin incision was made along the medial side of the patella. The cartilage defect site was exposed *via* a 4-cm longitudinal arthrotomy (Figure 2A). Multiple holes were made in the patellar subchondral bone using a 5 mm drill bit (Figure 2B), and CARTISTEM was injected (Figure 3C). Subsequently, medial patellofemoral ligament repair was performed.

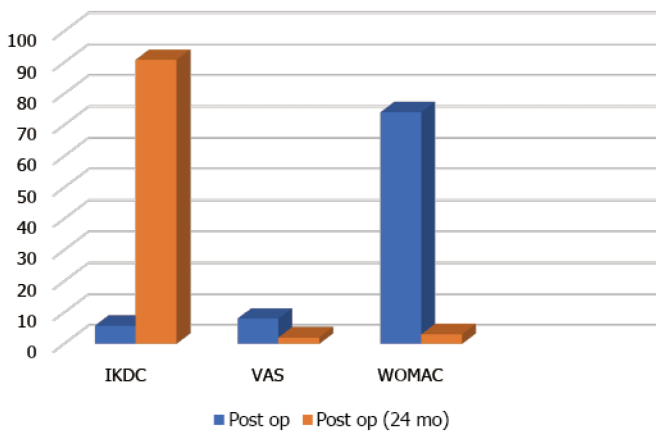
OUTCOME AND FOLLOW-UP

The patient was required to rest while wearing a knee brace for 3 d postoperatively. On postoperative day 4, he began performing a range of motion exercises using a continuous passive motion machine, quadriceps strengthening exercises and ankle pump exercises. On postoperative day 7, full weight-bearing walking with a hinged knee brace was permitted.

Cartilage regeneration was observed on follow-up MRI 2 years postoperatively (Figure 1C and D). Comparison of the International Knee Documentation Committee score, the visual analog scale score, and the McMaster Universities Osteoarthritis Index score before and 2 years after surgery indicated improvement, from 5.7 to 90.8, 8 to 2, and 74 to 3, respectively (Figure 4).

DISCUSSION

Patellar cartilage defects are frequently associated with trauma-induced acute patellar dislocation. In the report by Song *et al*[6], 95% (37/39) of knees with acute patellar dislocation had patellar cartilage defects. The treatment of large patellar cartilage defects is challenging. Using ACI, Vasiliadis *et al*[7] achieved satisfactory results in 92 patients with patellar or trochlear cartilage damage (mean size of the defect: 5.5 cm², average follow-up time: 12.6 years). After treatment, these patients had a high level of



DOI: 10.12998/wjcc.v10.i34.12665 Copyright ©The Author(s) 2022.

Figure 4 Clinical improvement. Visual analog scale, International Knee Documentation Committee (IKDC), visual analog scale (VAS), and McMaster Universities Osteoarthritis Index (WOMAC) scores show clinical improvement 2 years after human umbilical cord blood-derived mesenchymal stem cell implantation.

accessible whenever required[3,5,6].

Treatment of juvenile osteochondral defects, especially large defects, using hUCB-MSCs has been previously reported[3]. Our patient had a large patellar cartilage defect with accompanying acute patellar dislocation. Cartilage regeneration was observed 18 mo after hUCB-MSC implantation, as indicated by MRI findings and clinical scores. To the best of our knowledge, this is the first detailed description of the results of hUCB-MSC treatment of a large patellar cartilage defect with patellar dislocation.

CONCLUSION

hUCB-MSCs are a potential treatment option for large patellar cartilage defects with patellar dislocation. Cultured cell therapy, including stem cells, could be more appropriate for large chondral defects.

FOOTNOTES

Author contributions: Song JS and Song KJ conceived the study and wrote the manuscript; Hong KT participated in its design and coordination and helped to draft the manuscript; Kim SJ analyzed data; All authors read and approved the final manuscript.

Informed consent statement: Informed written consent was obtained from the patient's parents.

Conflict-of-interest statement: All authors report no relevant conflict of interest for this article.

CARE Checklist (2016) statement: The authors have read the CARE Checklist (2016), and the manuscript was prepared and revised according to the CARE Checklist (2016).

Open-Access: This article is an open-access article that was selected by an in-house editor and fully peer-reviewed by external reviewers. It is distributed in accordance with the Creative Commons Attribution NonCommercial (CC BY-NC 4.0) license, which permits others to distribute, remix, adapt, build upon this work non-commercially, and license their derivative works on different terms, provided the original work is properly cited and the use is non-commercial. See: <https://creativecommons.org/licenses/by-nc/4.0/>

Country/Territory of origin: South Korea

ORCID number: Jun-Seob Song 0000-0003-3918-4356; Ki-Taek Hong 0000-0001-6330-5301; Seok Jung Kim 0000-0002-9116-8786.

S-Editor: Wu YXJ

L-Editor: Filipodia

P-Editor: Wu YXJ

REFERENCES

- 1 **Gracitelli GC**, Meric G, Pulido PA, Görtz S, De Young AJ, Bugbee WD. Fresh osteochondral allograft transplantation for isolated patellar cartilage injury. *Am J Sports Med* 2015; **43**: 879-884 [PMID: 25596614 DOI: 10.1177/0363546514564144]
- 2 **Nomura E**, Inoue M, Kurimura M. Chondral and osteochondral injuries associated with acute patellar dislocation. *Arthroscopy* 2003; **19**: 717-721 [DOI: 10.1016/S0749-8063(03)00401-8]
- 3 **Park YB**, Song M, Lee CH, Kim JA, Ha CW. Cartilage repair by human umbilical cord blood-derived mesenchymal stem cells with different hydrogels in a rat model. *J Orthop Res* 2015; **33**: 1580-1586 [PMID: 26019012 DOI: 10.1002/jor.22950]
- 4 **Song JS**, Hong KT, Kim NM, Jung JY, Park HS, Chun YS, Kim SJ. Cartilage regeneration in osteoarthritic knees treated with distal femoral osteotomy and intra-lesional implantation of allogenic human umbilical cord blood-derived mesenchymal stem cells: A report of two cases. *Knee* 2019; **26**: 1445-1450 [PMID: 31443940 DOI: 10.1016/j.knee.2019.07.017]
- 5 **Song JS**, Hong KT, Kim NM, Jung JY, Park HS, Kim YC, Shetty AA, Kim SJ. Allogenic umbilical cord blood-derived mesenchymal stem cells implantation for the treatment of juvenile osteochondritis dissecans of the knee. *J Clin Orthop Trauma* 2019; **10**: S20-S25 [PMID: 31700204 DOI: 10.1016/j.jcot.2019.03.025]
- 6 **Song JS**, Hong KT, Kim NM, Jung JY, Park HS, Lee SH, Cho YJ, Kim SJ. Implantation of allogenic umbilical cord blood-derived mesenchymal stem cells improves knee osteoarthritis outcomes: Two-year follow-up. *Regen Ther* 2020; **14**: 32-39 [PMID: 31988992 DOI: 10.1016/j.reth.2019.10.003]
- 7 **Vasiliadis HS**, Lindahl A, Georgoulis AD, Peterson L. Malalignment and cartilage lesions in the patellofemoral joint treated with autologous chondrocyte implantation. *Knee Surg Sports Traumatol Arthrosc* 2011; **19**: 452-457 [PMID: 20845030 DOI: 10.1007/s00167-010-1267-1]



Published by **Baishideng Publishing Group Inc**
7041 Koll Center Parkway, Suite 160, Pleasanton, CA 94566, USA

Telephone: +1-925-3991568

E-mail: bpgoffice@wjgnet.com

Help Desk: <https://www.f6publishing.com/helpdesk>

<https://www.wjgnet.com>

